

Received on 16 February 2016; received in revised form, 18 March 2016; accepted, 26 March 2016; published 30 April 2016

## MEDICINAL PLANTS USED IN HEPATOPROTECTIVE: A REVIEW

Dilip Kumar Chanchal<sup>\*</sup>, Surabhi Rashi, Pankaj Singh Niranjana, Shashi Alok and Ravi Rajput

Department of Pharmacognosy, Institute of Pharmacy, Bundelkhand University, Jhansi - 248128, Uttar Pradesh, India.

**ABSTRACT:** Liver is a vital organ play a major role in the metabolism and excretion of xenobiotics from the body. Liver injury or liver dysfunction is a major health problem that challenges not only health care professionals but also the pharmaceutical industry and drug regulatory agencies. Modern medicine has provided us many drugs that alleviate liver diseases but compared to it herbal medicine; herbal is preferred because they are cost-effective and considered to be a safe approach for treatment with minimal side effects. Herbal medicines have been used in the treatment of liver diseases for a long time. Several herbal preparations are available in the market. Many herbs have been proven to be efficient as hepatoprotective agents while many more are claimed to be hepatoprotective but be deficient in any such scientific substantiation to support such claims. Clinical research in this century has confirmed the efficacy of several plants in the treatment of liver disease. Hence, this review article contributes to the knowledge of reported indigenous plants, which are prevalent for the prevention and treatment of liver disorders.

**Keywords:** Liver, Metabolism, Hepatoprotective, Herbal medicines

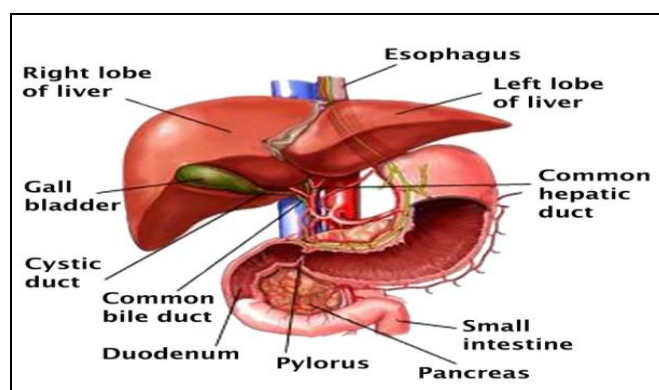
**Correspondence to Author:**  
Mr. Dilip Kumar Chanchal

Department of Pharmacognosy, Institute of Pharmacy, Bundelkhand University, Jhansi - 248128, Uttar Pradesh, India.

**E-mail:** chanchaldilip014@gmail.com

**INTRODUCTION:** The liver is a vital organ of vertebrates and some other animals.<sup>1</sup> Terminology related to the liver often starts in *hepar-* or *hepat-* from the Greek word for liver, *hēpar*<sup>2,3</sup>. In human beings, it is located in the upper right quadrant of the abdomen, below the diaphragm. It is a reddish brown wedge-shaped organ with four lobes of unequal size and shape. A human liver normally weighs 1.44–1.66 kg (3.2–3.7 lb)<sup>4</sup>. It is both the largest internal organ and the largest gland in the human body. The gallbladder, a small pouch that sits just under the liver, stores bile produced by the liver<sup>5</sup>.

The falciform ligament, visible on the front of the liver, divides the liver into a left and a much larger right lobe. From the visceral surface, the two additional lobes are located between the right and left lobes, one in front of the other. A line can be imagined running from the left of the vena cava and all the way forward to divide the liver and gallbladder into two halves<sup>6</sup>. This line is called Cantlie's line.

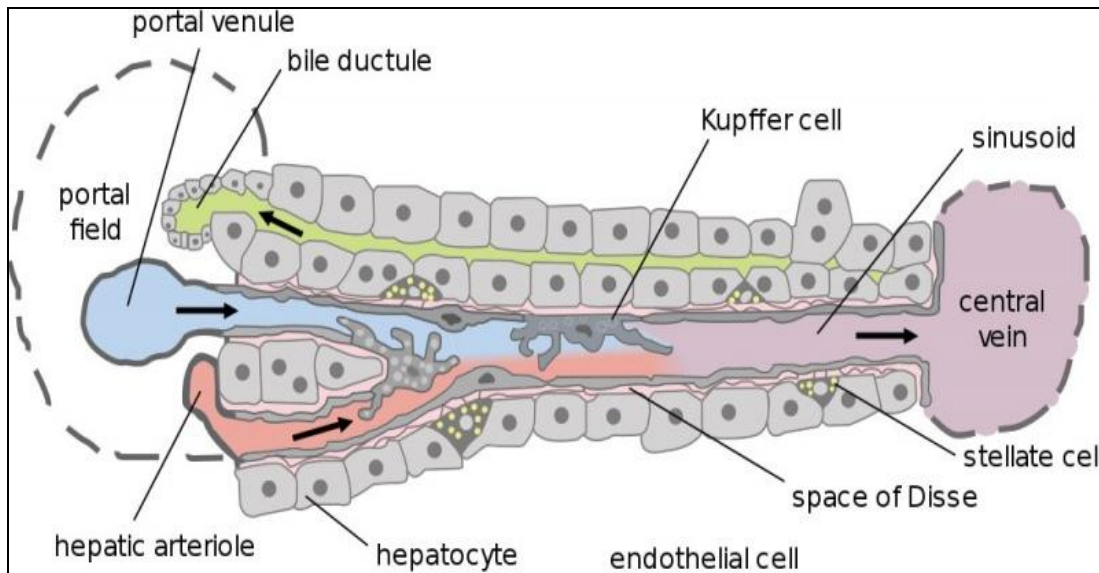


**FIG. 1: HUMAN LIVER WITH OTHER ORGANS**

<b>QUICK RESPONSE CODE</b> 	<b>DOI:</b> 10.13040/IJPSR.0975-8232.IJLSR.2(4).61-77
	The article can be accessed online on <a href="http://www.ijlsr.com">www.ijlsr.com</a>
<b>DOI link:</b> <a href="http://dx.doi.org/10.13040/IJPSR.0975-8232.IJLSR.2(4).61-77">http://dx.doi.org/10.13040/IJPSR.0975-8232.IJLSR.2(4).61-77</a>	

Gross anatomy traditionally divided the liver into two portions— a right and a left lobe, as viewed from the front (diaphragmatic) surface; but the

underside (the visceral surface) shows it to be divided into four lobes and includes the caudate and quadrate lobes<sup>7</sup>.



**FIG. 2: CELL, DUCTS AND BLOOD VESSELS**

The study of microscopic anatomy shows two major types of liver cell: parenchymal cells and non-parenchymal cells. 70–85% of the liver volume is occupied by parenchymal hepatocytes. Non-parenchymal cells constitute 40% of the total number of liver cells but only 6.5% of its volume<sup>8</sup>. The liver sinusoids are lined with two types of cell, sinusoidal endothelial cells, and phagocytic Kupffer cells<sup>9</sup>. Hepatic stellate cells are non-parenchymal cells found in the space of Disse, between a sinusoid and a hepatocyte<sup>8</sup>. Additionally, intrahepatic lymphocytes are often present in the sinusoidal lumen<sup>8</sup>.

The visceral surface or inferior surface is uneven and concave. It is covered in peritoneum apart from where it attaches the gallbladder and the porta hepatis<sup>10</sup>. Microscopically, each liver lobe is seen to be made up of hepatic lobules. The lobules are roughly hexagonal and consist of plates of hepatocytes radiating from a central vein<sup>11</sup>. The central vein joins the hepatic vein to carry blood out from the liver. A distinctive component of a lobule is the portal triad, which can be found running along each of the lobule's corners. The portal triad, misleadingly named, consists of five structures: a branch of the hepatic artery, a branch of the hepatic portal vein, and a bile duct, as well as lymphatic vessels and a branch of the vagus nerve<sup>12</sup>. Between the hepatocyte plates are liver

sinusoids, which are enlarged capillaries through which blood from the hepatic portal vein and hepatic artery enter via the portal triads, then drains to the central vein<sup>13</sup>. The lobules are held together by fine areolar tissue which extends into the structure of the liver, by accompanying the vessels (veins and arteries) ducts and nerves through the hepatic portal, as a fibrous capsule called Glisson's capsule<sup>13</sup>. The whole surface of the liver is covered in a serious coat derived from the peritoneum and this has an inner fibrous coat (Glisson's capsule) to which it has firmly adhered. The fibrous coat is of areolar tissue and follows the vessels and ducts to support them.

The liver is the only human internal organ capable of natural regeneration of lost tissue; as little as 25% of a liver can regenerate into a whole liver<sup>14</sup>. This is, however, not true regeneration but rather compensatory growth in mammals<sup>15</sup>. The lobes that are removed do not regrow, and the growth of the liver is a restoration of function, not original form. This contrasts with true regeneration where both original function and form are restored. In some other species, such as fish, the liver undergoes true regeneration by and size of the organ<sup>16</sup>. In the liver, large areas of the tissues are formed, but for the formation of new cells, there must be a sufficient amount of material, so the circulation of the blood becomes more active<sup>17</sup>.

The liver has a wide range of functions, including detoxification of various metabolites, protein synthesis, and the production of biochemicals necessary for digestion<sup>18</sup>. The liver is a gland and plays a major role in metabolism with numerous functions in the human body, including regulation of glycogen storage, decomposition of red blood cells, plasma protein synthesis, hormone production, and detoxification<sup>18</sup>. It is an accessory digestive gland and produces bile, an alkaline compound which aids in digestion via the emulsification of lipids

The liver's highly specialized tissue consisting of mostly hepatocytes regulates a wide variety of high-volume biochemical reactions, including the synthesis and breakdown of small and complex molecules, many of which are necessary for normal vital functions<sup>19</sup>. Estimates regarding the organ's total number of functions vary, but textbooks generally cite it being around 500<sup>20</sup>.

The liver supports almost every organ in the body and is vital for survival. Because of its strategic location and multidimensional functions, the liver is also prone to many diseases<sup>21</sup>. The bare area of the liver is a site that is vulnerable to the passing of infection from the abdominal cavity to the thoracic cavity. The classic symptoms of liver damage include the following:

- Pale stools occur when stercobilin, a brown pigment, is absent from the stool. Stercobilin is derived from bilirubin metabolites produced in the liver.
- Dark urine occurs when bilirubin mixes with urine
- Jaundice (yellow skin and whites of the eyes) this is where bilirubin deposits in the skin, causing an intense itch. Itching is the most common complaint by people who have liver failure. Often this itch cannot be relieved by drugs.
- Swelling of the abdomen, ankles, and feet occurs because the liver fails to make albumin.
- Excessive fatigue occurs from a generalized loss of nutrients, minerals, and vitamins.

- Bruising and easy bleeding are other features of liver disease. The liver makes substances which help prevent bleeding. When liver damage occurs, these substances are no longer present, and severe bleeding can occur<sup>22</sup>.
- Pain in the upper right quadrant can result from the stretching of Glisson's capsule in conditions of hepatitis and pre-eclampsia.



FIG. 3: EVALUATION OF LIVER DISEASE

Few of the liver diseases are as follows:

**Alcohol and the Liver:** Alcohol affects everyone. When a person has a drink, the alcohol is absorbed directly through the wall of the stomach and intestine into the bloodstream, where it is distributed rapidly throughout the body. The alcohol changes the function of each cell that it enters. The liver processes everything a person ingests, including alcohol. Only a certain quantity of alcohol can be detoxified over some time. In the meantime, excess alcohol affects the brain, heart, muscles, and other tissues of the body. When the liver has too much alcohol to handle, normal liver function may be interrupted, leading to a chemical imbalance.

If the liver is required to detoxify alcohol continuously, liver cells may be destroyed or altered resulting in fat deposits (fatty liver), and more seriously, either inflammation (alcoholic hepatitis), and/or permanent scarring (cirrhosis), moreover, liver cancer can also result from alcohol-induced liver disease and including hepatitis C. Therefore, anyone with hepatitis C, or any other form of liver disease, should not drink alcohol. Symptoms and complications arising from liver damage include fatigue, loss of appetite, lowered resistance to infections, jaundice (yellowing of the skin and eyes), swelling of the abdomen, internal bleeding, confusion, and kidney failure.

**Cirrhosis:** Cirrhosis is a condition that results from permanent damage or scarring of the liver. This leads to a blockage of blood flow through the liver and prevents normal metabolic and regulatory processes.

Blockage of the normal flow of blood through the liver leads to swelling of the liver and potentially the spleen. Blood from the intestines is then forced to find a new way around the liver through new vessels. Some of these new blood vessels called "varices" which form primarily in the stomach and esophagus become quite large. These variances may rupture due to high blood pressure (portal hypertension) and thin vessel walls, causing bleeding in the upper stomach or esophagus.

Individuals with cirrhosis may bleed and bruise easily due to a decrease in proteins required for blood clotting.

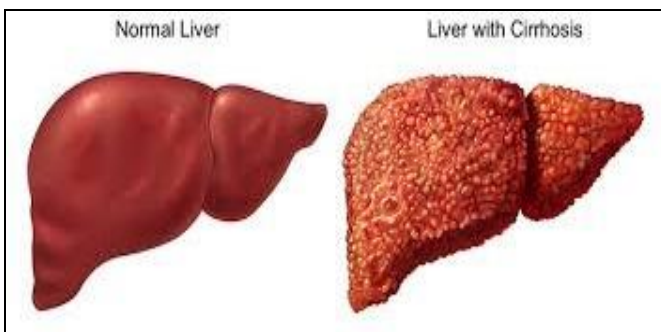


FIG. 4: HEALTHY LIVER AND LIVER WITH CIRRHOSIS

The major causes of cirrhosis are as follows:

- Chronic alcoholism
- Viral infections caused by chronic viral hepatitis (types B, C, and D)
- Metabolic diseases such as alpha-1-antitrypsin deficiency, galactosemia, and glycogen storage disorders
- Inherited diseases such as Wilson disease and hemochromatosis
- Biliary cirrhosis resulting from diseases such as primary biliary cirrhosis (PBC) and primary sclerosing cholangitis (PSC)
- Toxic hepatitis caused by severe reactions to prescribed drugs or prolonged exposure to environmental toxins

- Repeated bouts of heart failure with liver congestion.

People in the early stages of cirrhosis have few symptoms. Some symptoms an individual may notice include:

- Loss of appetite
- Nausea
- Weight loss
- Fatigue
- Weakness
- Exhaustion.

**Gallstones:** Gallstones are solid lumps of cholesterol crystals or pigment material that form in the gallbladder.

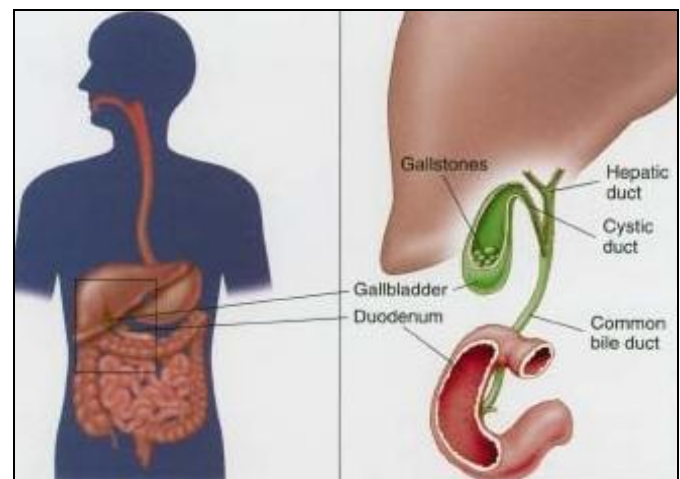


FIG. 5: GALLSTONE

They are formed when some fatty components (such as cholesterol) are not easily dissolved in bile. When there are too much of these components in bile, they precipitate and form solid crystals. This clump together forming gallstones - also known as cholelithiasis. There are different types of gallstones, depending on which component of the bile has solidified. Also, the stones can vary in size ranging from tiny, sand-like particles less than one millimeter in diameter to more than four centimeters in diameter. Patients with symptomatic gallstones experience severe abdominal pain and may suffer further complications such as jaundice (yellowing of the skin and eyes) and inflammation of the gallbladder, bile ducts, liver or pancreas.

However, about 80 percent of people who have gallstones have no symptoms. These people are said to have so-called "silent" gallstones with no associated pain. Gas and indigestion are not specific symptoms of gallbladder or gallstone disease.

Silent gallstones are detected incidentally during the investigation of another problem; Gallstones are usually diagnosed by ultrasound. Other procedures, such as x-rays, may also be used.

**Hemochromatosis:** It is an inherited disease in which the body absorbs too much iron from the diet. The liver is the first organ to store iron and when its storage capacity is exhausted, the iron continues to accumulate in the heart, the pituitary gland and elsewhere in the body.

Normally, only enough iron to meet the body's daily requirements is absorbed; the remainder is usually excreted through the bowels. In hemochromatosis, however, iron continues to be absorbed and stored in different organs and tissues long after body needs are met. If untreated, damage to the liver, heart, and pancreas may eventually lead to death. Hemochromatosis is hereditary. The liver begins to retain iron at birth, but it may take 20 to 30 years before symptoms manifest themselves. In the early stages of hemochromatosis, there may be no signs, but when symptoms begin to appear, they include:

- Fatigue
- Swelling in the joints (arthritis), particularly in the knuckles of the middle and index fingers

In the later stages of the disease, symptoms include:

- Abdominal pain or tenderness
- Yellowing of the skin and eyes (jaundice)
- Distention of the abdomen
- Bleeding from dilated veins in the esophagus development of diabetes
- The skin may have a bronze or grey color
- Excessive hunger and thirst

- Frequent urination.

**Liver Cancer:** Many factors may play a role in the development of cancer. Because the liver filters blood from all parts of the body, cancer cells from elsewhere can lodge in the liver and start to grow. Cancers that begin in the gut often spread to the liver. The ability of the liver to regenerate may also be linked to the development of liver cancers. There are many types of liver tumors, only some of which are cancers. The most important classification is whether the tumours are benign (relatively harmless) or malignant (capable of spreading from the liver and thus more serious).

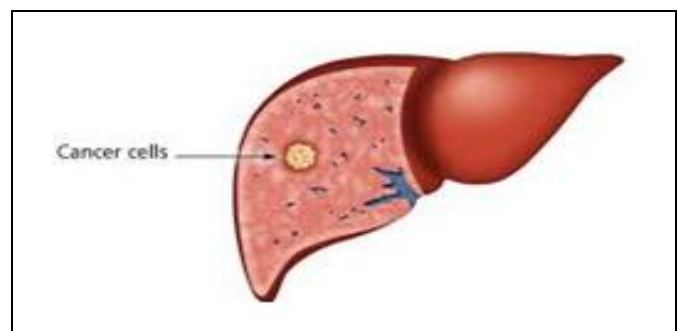


FIG. 6: LIVER CANCER

Benign Tumours, Hemangioma is the most common type of benign liver tumor. It is an abnormal growth of blood vessels of the liver that begins in the fetus. More than 10% of the normal population has hemangiomas in the liver. Most people with hemangiomas have no symptoms and require no treatment. Some hemangiomas may rarely enlarge and bleed, in which case they may require surgical removal. Hepatic adenomas are benign tumors of liver cells. Most do not cause symptoms and do not require treatment. However, if they are large, they may cause pain or blood loss and may need to be removed. Hepatic adenomas occur more frequently in women and seem to be triggered in some cases by the birth control pill or by pregnancy. Focal nodular hyperplasia (FNH) is a tumor-like growth of several cell types. Although FNH tumors are benign, it can be hard to distinguish them from liver cancers.

Malignant Tumours, the most common form of primary liver cancer (cancer that starts in the liver) in adults is called hepatocellular carcinoma (HCC). It is a cancer of liver cells. This type of cancer can have different growth patterns. Some begin as a single tumor that grows larger. It may spread to

other parts of the liver in the later stages of the disease.

Liver cancer may also develop in more than one site in the liver and may grow into multiple tumors. This pattern is most often seen in people with liver cirrhosis.

Another liver cancer is called cholangiocarcinoma. It originates in the small bile ducts which are tubes that carry bile to the gall bladder.

Most often, however, when cancer occurs in the liver, it did not start there but spread to the liver from cancer that began somewhere else in the body. These types of cancers are named after the place where they began (primary site) and are considered secondary liver cancers or cancer metastases. For example, cancer that started in the lung and spread to the liver is called metastatic lung cancer with spread to the liver. Secondary liver cancers are 30 times more prevalent than primary liver cancers.

In the early stages, liver cancer does not cause symptoms. Some common symptoms of advanced liver cancer include:

- Weight loss
- Loss of appetite
- Abdominal pain
- Jaundice
- Fluid in the abdomen.

**Alagille Syndrome:** It is an inherited disorder that mimics other forms of prolonged liver disease seen in infants and young children. Specifically, Alagille syndrome is also associated with cardiac disease, eye, and skeletal findings, and a characteristic facial appearance. Alagille syndrome is caused by changes, or mutations, in one of two genes, usually *JAGGED1* or occasionally *NOTCH2*. Each affected adult or child may have all or only a few of the features of the syndrome.

Typically, symptoms of the illness are jaundice and poor growth within the first three months of life. Later, there is persistent jaundice, severe itching, fatty deposits in the skin (xanthomas), and poor

growth during early childhood. Frequently the disease stabilizes between ages five and eight with an improvement in symptoms. There is also a specific facial appearance shared by children with Alagille syndrome that makes them easily recognizable. The features include a prominent, broad forehead, deep-set eyes, a straight nose, and a small pointed chin. The majority of children with Alagille syndrome have an abnormality of the eyes in which an extra, circular line on the surface of the eye can be detected by a specialized eye examination. However, it does not lead to any vision problems.

**Autoimmune Hepatitis:** It is a disease characterized by chronic inflammation of the liver. Autoimmune refers to the body's immune system attacking another part of the body. The exact mechanism whereby the body's immune system attacks the liver is not yet known. It appears that certain types of white blood cells (the type of blood cell that usually fights infection), in addition to attacking foreign substances (e.g., germs and viruses) misread liver cells as foreign substances and start attacking these cells. The type of damage that follows is known as chronic hepatitis. Several other conditions can cause identical patterns of liver damage.

These include viruses such as hepatitis B and hepatitis C, certain types of drugs, and overload of certain metals such as copper and iron in the liver. In many patients, there will be no symptoms at all. The patient will feel perfectly healthy. The condition may be detected on a routine blood test by an elevation in levels of certain enzymes that the liver makes. Other patients may experience fatigue, decreased appetite, drowsiness, or even aches or pains in the muscles or joints. Some patients may notice jaundice or yellowish discoloration of the skin and whites of the eyes as the first symptom.

**Biliary Atresia:** In this, the bile duct that leads from the liver to the intestine becomes damaged, preventing bile from leaving the liver. In the early stages, the bile duct outside the liver is mainly affected, but in later stages, bile ducts inside the liver are also damaged. This can lead to building up of bile in the liver, which can be harmful to the liver. Unless bile flow can be established, liver function is gradually lost and affected children

rarely survive beyond two years of age. It is a relatively rare disease that begins in early infancy.

Bile is a yellow-green fluid made in the liver and stored in the gallbladder. It helps with digestion and absorption of dietary fats and fat-soluble vitamins. It is also necessary for removing waste products from metabolism and toxins from the body.

The cause of biliary atresia is not known. It is not contagious, and it cannot be passed from one child to another. Biliary atresia is usually diagnosed during the first two months of life. Common signs are:

- Newborn jaundice that does not improve by two weeks of age, or jaundice that appears after two weeks of age
- Dark urine and pale, clay-colored stools
- Enlarged liver or swollen abdomen.

**Galactosemia:** This disease is caused by elevated levels of galactose (a sugar in milk) in the blood resulting from a deficiency of the liver enzyme required for its metabolism (breakdown). It is a rare hereditary disease that can lead to cirrhosis in infants, and early, devastating illness if not diagnosed quickly. The disease usually appears in the first few days of life following the ingestion of breast milk or formula. Vomiting, liver enlargement, and jaundice are often the earliest signs of the disease, but bacterial infections (often severe), irritability, failure to gain weight, and diarrhea may also occur. If unrecognized in the newborn period, the disease may produce liver, brain, eye, and kidney damage.

**Reye's Syndrome:** It is a rare complication of common childhood respiratory infections, including chickenpox. Reye's syndrome is most common in school-aged children and teenagers, but cases also occur in infants. The illness is rare in adults.

Reye's syndrome should be suspected when vomiting begins three to seven days after the onset of the flu or chickenpox. Usually, the vomiting becomes increasingly severe over eight to 12 hours. When vomiting persists for more than 12 hours, or vomiting is associated with signs of brain disorder,

such as staring spells, stupor, delirium, or strange behavior, call your doctor. In the later stage of the disease, the child shows personality changes such as aggressive behavior and disorientation. Other symptoms may include confusion, slurred speech, agitated delirium with screaming and struggling, and an inability to recognize parents. This stage is a medical emergency.

Although Reye's syndrome can occur anytime, it is most frequent in January, February, and March, in association with influenza and similar respiratory infections. About one-third of the cases of Reye's syndrome occurs as a complication of chickenpox, usually three or four days after the rash appears.

Vomiting on the first day of illness, especially when accompanied by diarrhea, is not typically due to Reye's syndrome. In such cases, children are usually alert and active. They may be suffering from acute infectious gastroenteritis.

Above are few of the popular and known diseases which affect the liver. Other than these some hepatotoxins majorly damage liver. Hepatotoxicity, in most cases is due to free radical. Free radicals generated by the metabolism of toxicants initiate the toxicity cascade<sup>23</sup>. Hepatotoxins like Carbon tetrachloride, Paracetamol, D-Galactosamine, and Thioacetamide.

**Carbon Tetrachloride:** The hepatotoxicity of CCl<sub>4</sub> is due to the formation of the highly reactive trichloromethyl free radical in the body which attacks the polyunsaturated fatty acids of the membrane of the endoplasmic reticulum. Carbon tetrachloride poisoning leads rapidly to the cessation of movement of large quantities of triglycerides from the liver to the plasma leading to fatty liver<sup>24</sup>. If the damage is severe, it leads to an abnormal increase in liver enzymes followed by hepatocellular necrosis.

**Paracetamol:** Paracetamol is metabolically activated by cytochrome P450 to a reactive metabolite that covalently binds to protein<sup>25</sup>. The reactive metabolite responsible for hepatotoxicity is N-acetyl-p-benzoquinoneimine, which reacts with N-acetyl cysteine<sup>26</sup>. Although considered safe at therapeutic doses, in overdose, it produces centrilobular hepatic necrosis that can be fatal<sup>27</sup>.

Various mechanisms leading to paracetamol toxicity includes

- a. Increased formation of superoxide anions which cause lipid peroxidation (oxidative stress) via hydrogen peroxide formation<sup>28</sup>.
- b. Decreased glutathione concentrations in centrilobular cells<sup>29</sup>.

**D-galactosamine:** Galactosamine administration induces an inflammatory response in the liver that biochemically and histologically resembles viral hepatitis<sup>30</sup>. A single administration causes hepatocellular necrosis and fatty liver<sup>31</sup>. It causes the appearance of specific lesions in liver cells, characterized by inhibition of nuclear RNA and protein synthesis<sup>32</sup>.

**Thioacetamide:** Thioacetamide, originally used as a fungicide is a potent hepatotoxic and is bioactivated by CYP450 and flavin-containing monooxygenase (FMO) systems to sulfine (sulfoxide) and sulfene (sulfone) metabolites, which causes centrilobular necrosis<sup>33, 34</sup>. This metabolite causes liver fibrosis. Thioacetamide interferes with the movement of RNA from the nucleus to cytoplasm, which may cause membrane injury<sup>35</sup>.

Therefore, maintenance of a healthy liver is essential for the overall well being of an individual<sup>36</sup>. Modern medicines have a little to offer for the alleviation of hepatic diseases, and it is chiefly the plant-based preparations which are employed for their treatment of liver disorders<sup>37</sup>.

Herbal medicines are the most lucrative form of traditional medicine on which about 80% of the population depends (WHO traditional medicine facts sheet no 134. Dec 2008).

Herbal drugs have gained importance and popularity in recent years because of their safety, efficacy, and cost-effectiveness. The association of medical plants with other plants in their habitat also influences their medicinal values in some cases.

One of the important and well-documented uses of plant products is their use as hepatoprotective agents. Hence, there is an ever-increasing need for safe hepatoprotective agent<sup>38</sup>. It has been reported that about 160 phytoconstituents from 101 medicinal plants have hepatoprotective activity<sup>39</sup>.

In this review, majorly hepatoprotective activity contained plant names are detailed

**TABLE 1: HEPATOPROTECTIVE ACTIVITY CONTAINED PLANTS**

Plants	Family	Part used
<i>Casuarina equisetifolia</i> <sup>40</sup>	Casuarinaceae	Leaf and Bark
<i>Cajanus cajan</i> <sup>40</sup>	Papilionaceae	Whole plant
<i>Glycosmis pentaphylla</i> <sup>40</sup>	Rutaceae	Leaf, Bark
<i>Bixa orellana</i> <sup>40</sup>	Bixaceae	Seed
<i>Physalis minima</i> <sup>40</sup>	Solanaceae	Whole plant
<i>Argemone Mexicana</i> <sup>40</sup>	Papaveraceae	Leaf and flower
<i>Caesalpinia bonduc</i> <sup>40</sup>	Caesalpinaceae	Leaf and bark
<i>Carthamus tinctoriu</i> <sup>41</sup>	Compositae	Flower
<i>Ardisia solanacea</i> <sup>42</sup>	Myrsinaceae	Leaves
<i>Delonix regia</i> <sup>43</sup>	Caesalpinaceae	Aerial parts
<i>Aphanamixis polystachya</i> <sup>44</sup>	Meliaceae	Leaves
<i>Solanum pubescens</i> <sup>45</sup>	Solanaceae	Whole plant
<i>Coriandrum sativum</i> <sup>46</sup>	Apiaceae	Whole plant
<i>Plumbago zeylanica</i> <sup>47</sup>	Plumbaginaceae	Aerial parts
<i>Cardiospermum helicacabum</i> <sup>48</sup>	Sapindaceae	Stem
<i>Luffa acutangula</i> <sup>49</sup>	Cucurbitaceae	Leaves
<i>Epaltes divaricata</i> <sup>50</sup>	Compositae	Whole plant
<i>Tagetes erecta</i> <sup>51</sup>	Asteraceae	Flower branches
<i>Zizphus rotundifolia</i> <sup>52</sup>	Rhamnaceae	Leaves
<i>Millettia aboensis</i> <sup>53</sup>	Fabaceae	Roots
<i>Ficus carica</i> <sup>54</sup>	Moraceae	Leaves



<i>Morus alba</i> <sup>55</sup>	Moraceae	Leaves
<i>Alchornea cordifolia</i> <sup>56</sup>	Euphorbiaceae	Leaves
<i>Leucophyllum frutescens</i> <sup>57</sup>	Scrophulariaceae	Aerial parts
<i>Carissa carandas</i> <sup>58</sup>	Apocynaceae	Roots
<i>Sesamum indicum</i> <sup>59</sup>	Pedaliaceae	Seeds
<i>Flacourtia indica</i> <sup>60</sup>	Flacourtiaceae	Leaves
<i>Hippophae rhamnoides</i> <sup>61</sup>	Elaeagnaceae	Leaves
<i>Apium graveolens</i> <sup>62</sup>	Apiaceae	Seeds
<i>Croton oblongifolius</i> <sup>62</sup>	Euphorbiaceae	Whole plant
<i>Hypericum japonicum</i> <sup>63</sup>	Hypericaceae	Whole plant
<i>Cinnamomum zeylanicum</i> <sup>64</sup>	Lauraceae	Bark
<i>Launea intybacea</i> <sup>65</sup>	Asteraceae	Aerial parts
<i>Mimosa pudica</i> <sup>66</sup>	Mimosaceae	Leaves
<i>Polygala javana</i> <sup>67</sup>	Polygalaceae	Whole plant
<i>Marsilea minuta</i> <sup>68</sup>	Marsileaceae	Whole plant
<i>Ficus bengalensis</i> <sup>69</sup>	Moraceae	Leaves
<i>Chenopodium album</i> <sup>70</sup>	Chenopodiaceae	Aerial parts
<i>Psidium guajava</i> <sup>71</sup>	Myrtaceae	Leaves
<i>Rhododendron arboretum</i> <sup>72</sup>	Ericaceae	Leaves
<i>Diteracanthus patulus</i> <sup>73</sup>	Acanthaceae	Leaves
<i>Cuscuta reflexa</i> <sup>74</sup>	Cuscutaceae	Aerial parts
<i>Crassocephalum crepidioides</i> <sup>75</sup>	Asteraceae	Whole plant
<i>Glycyrrhiza glabra</i> <sup>76</sup>	Fabaceae	Roots
<i>Gundelia tourenfortii</i> <sup>77</sup>	Asteraceae	Footstalks
<i>Coptidis rhizome</i> <sup>78</sup>	Ranunculaceae	Whole plant
<i>Carica papaya</i> <sup>79</sup>	Caricaceae	Seeds
<i>Cichorium intybus</i> <sup>80</sup>	Asteraceae	Leaves
<i>Scoparia dulcis</i> <sup>81</sup>	Scrophulariaceae	Whole plant
<i>Indigofera tinctoria</i> <sup>82</sup>	Leguminosae ( Papilionatae)	Whole plant
<i>Solanum trilobactum</i> <sup>83</sup>	Solanaceae	Whole plant
<i>Pterocarpus marsupium</i> <sup>84</sup>	Papilionaceae	Stem bark
<i>Pterocarpus santalinus</i> <sup>85</sup>	Fabaceae	Stem bark
<i>Curculigo orchinoides</i> <sup>86</sup>	Amaryllidaceae	Rhizomes
<i>Phoenix dactylifera</i> <sup>87</sup>	Palmae	Fruit
<i>Asteracantha longifolia</i> <sup>88</sup>	Acanthaceae	Whole plant
<i>Strychnos potatorum</i> <sup>89</sup>	Longaniaceae	Seeds
<i>Vitex trifolia</i> <sup>90</sup>	Verbenaceae	Leaves
<i>Capparis spinosa</i> <sup>91</sup>	Capparidaceae	Root bark
<i>Lawsonia alba</i> <sup>92</sup>	Lythraceae	Bark
<i>Carissa opaca</i> <sup>93</sup>	Apocynaceae	Leaves
<i>Azima tetracantha</i> <sup>94</sup>	Salvadoraceae	Leaves
<i>Dragea volubilis</i> <sup>95</sup>	Asclepiadaceae	Leaves
<i>Coccinia indica</i> <sup>96</sup>	Curcubitaceae	Fruits
<i>Sida rhombifolia</i> <sup>97</sup>	Malvaceae	Whole plant
<i>Tabebuia rosea</i> <sup>98</sup>	Bignoniaceae	Leaves
<i>Ichnocarpus frutescens</i> <sup>99</sup>	Apocynaceae	Whole plant
<i>Vanilla planifolia</i> <sup>100</sup>	Orchidaceae	Beans
<i>Nilgiranthus ciliates</i> <sup>101</sup>	Acanthaceae	Bark
<i>Phyllanthus amarus</i> <sup>102</sup>	Phyllanthaceae	Leaves
<i>Aegle marmelos</i> <sup>102</sup>	Rutaceae	Leaves
<i>Aloe vera</i> <sup>102</sup>	Xanthorrhoeaceae	Leaves
<i>Eclipta alba</i> <sup>102</sup>	Asteraceae	Leaves

<i>Solanum Indicum</i> <sup>102</sup>	Solanaceae	Leaves
<i>Maytenus emarginata</i> <sup>102</sup>	Celastraceae	Leaves
<i>Aerva lanata</i> <sup>103</sup>	Amaranthaceae	Whole plant
<i>Aerva sanguinolenta</i> <sup>104</sup>	Amaranthaceae	Leaves
<i>Gymnosporia emerginata</i> <sup>105</sup>	Celastraceae	Whole plant
<i>Marsdenia volubillis</i> <sup>105</sup>	Asclepiadaceae	Whole plant
<i>Carissa carandas</i> <sup>106</sup>	Apocyanaceae	Roots
<i>Asparagus racemosa</i> <sup>107</sup>	Liliaceae	Roots
<i>Kigelia Africana</i> <sup>108</sup>	Bignoniaceae	Leaves
<i>Anogeissus acuminate</i> <sup>108</sup>	Combretaceae	Leaves
<i>Abelmoschus moschatus</i> <sup>109</sup>	Malvaceae	Seeds
<i>Cyperus articulatus</i> <sup>110</sup>	Cyperaceae	Rhizomes
<i>Thymus capitatus</i> <sup>111</sup>	Lamiaceae	Essential oils
<i>Salvia officinalis</i> <sup>111</sup>	Lamiaceae	Essential oils
<i>Solidago microglossa</i> <sup>112</sup>	Compositae	Leaves
<i>Macrotyloma uniflorum</i> <sup>113</sup>	Fabaceae	Seeds
<i>Tridax procumbens</i> <sup>114</sup>	Compositae	Whole plant
<i>Orthosiphon stamineus</i> <sup>115</sup>	Lamiaceae	Leaves
<i>Desmodium oojainens</i> <sup>116</sup>	Fabaceae	Bark
<i>Trianthema portulacastrum</i> <sup>117</sup>	Aizoaceae	Whole plant
<i>Acacia chatechu</i> <sup>118</sup>	Mimosaceae	Heartwood
<i>Feronia limonia</i> <sup>119</sup>	Rutaceae	Fruits
<i>Tecomella undulate</i> <sup>120</sup>	Bignoneaceae	Leaves
<i>Baliospermum montanum</i> <sup>121</sup>	Euphorbiaceae	Roots
<i>Cyathea gigantean</i> <sup>122</sup>	Cyatheaceae	Leaves
<i>Operculina turpethum</i> <sup>123</sup>	Convolvulaceae	Roots
<i>Tamarindus indica</i> <sup>124</sup>	Caesalpiniaceae	Fruits, seeds, leaves
<i>Berberis tinctoria</i> <sup>125</sup>	Berberidaceae	Leaves
<i>Azadirachta indica</i> <sup>126</sup>	Meliaceae	Leaves
<i>Ceiba pentandra</i> <sup>127</sup>	Bombacaceae	Stem bark
<i>Plumbago zeylanica</i> <sup>128</sup>	Plumbaginaceae	Roots
<i>Phyllanthus emblica</i> <sup>129</sup>	Euphorbiaceae	Fruits
<i>Pittosporum neelgherrense</i> <sup>130</sup>	Pittosporaceae	Stem bark
<i>Sphaeranthus amaranthoides</i> <sup>131</sup>	Compositae	Whole plant
<i>Olenlandia herbaceae</i> <sup>132</sup>	Rubiaceae	Whole plant
<i>Calotropis gigantean</i> <sup>133</sup>	Asclepiadaceae	Root bark
<i>Coldenia procumbens</i> <sup>134</sup>	Boraginaceae	Whole plant
<i>Portulaca oleraceae</i> <sup>135</sup>	Portulacaceae	Whole plant
<i>Betula utilis</i> <sup>136</sup>	Betulaceae	Bark
<i>Pterocarpus santalinus</i> <sup>137</sup>	Fabaceae	Heartwood
<i>Santolina chamaecyparissus</i> <sup>138</sup>	Asteraceae	Whole plant
<i>Polygala arvensis</i> <sup>139</sup>	Polygalaceae	Leaves
<i>Enicostemma axillare</i> <sup>140</sup>	Gentianaceae	Whole plant
<i>Solanum tuberosum (purple potato)</i> <sup>141</sup>	Solanaceae	Tubers
<i>Garcinia kola</i> <sup>142</sup>	Guttifera	Seeds
<i>Fumaria indica pugsley</i> <sup>143</sup>	Fumariaceae	Whole plant
<i>Leucas lavandulaefolia</i> <sup>144</sup>	Labiatae	Leaves
<i>Pisonia aculeate</i> <sup>145</sup>	Nyctaginaceae	Whole plant
<i>Phyllanthus niruri</i> <sup>146</sup>	Phyllanthaceae	Whole plant
<i>Vitex negundo</i> <sup>147</sup>	Lamiaceae	Leaves
<i>Momordica tuberosa</i> <sup>148</sup>	Cucurbitaceae	Tubers
<i>Tinispora crispa</i> <sup>149</sup>	Menispermaceae	Stem

<i>Zizyphus jujube</i> <sup>150</sup>	Rhamnaceae	Fruits
<i>Phoenix dactylifera</i> <sup>151</sup>	Aracaceae	Fruits
<i>Gardenia gummifera</i> <sup>152</sup>	Rubiaceae	Roots
<i>Albizia lebbek</i> <sup>153</sup>	Fabaceae	Leaves
<i>Wedelia calendulaceae</i> <sup>154</sup>	Compositae	Leaves
<i>Ceiba pentandra</i> <sup>155</sup>	Bombacaceae	Root
<i>Ipomoea aquatic</i> <sup>156</sup>	Convolvulaceae	Leaves
<i>Boerhaavia diffusa</i> <sup>157</sup>	Nyctaginaceae	Stem, leaves
<i>Anisochilus carnosus</i> <sup>157</sup>	Nyctaginaceae	Leaves
<i>Phyllanthus acidus</i> <sup>158</sup>	Euphorbiaceae	Leaves
<i>Artemisia aucheri</i> <sup>159</sup>	Compositae	Flowered
<i>Nigella sativa</i> <sup>160</sup>	Ranunculaceae	Seed oil
<i>Curcuma longa</i> <sup>161</sup>	Zingiberaceae	Rhizome
<i>Capparis deciduas</i> <sup>162</sup>	Capparaceae	Root bark
<i>Bosenbergia rotunda</i> <sup>163</sup>	Zingiberaceae	Rhizomes
<i>Feronia elephantum</i> <sup>164</sup>	Rutaceae	Leaves
<i>Optunia ficus indica</i> <sup>165</sup>	Cactaceae	Fruits
<i>Citrus paradise</i> <sup>165</sup>	Rutaceae	Fruits
<i>Matricaria chamomilla</i> <sup>165</sup>	Asteraceae	Essential oil
<i>Silybum marianum</i> <sup>165</sup>	Asteraceae	Crude extract
<i>Trigonella foenum graecum</i> <sup>166</sup>	Leguminosae	Seeds
<i>Jatropha curcas</i> <sup>166</sup>	Euphorbiaceae	Leaves
<i>Coccinia grandis</i> <sup>166</sup>	Curcubitaceae	Fruits
<i>Morinda citrifolia</i> <sup>166</sup>	Rubiaceae	Juice
<i>Ficus benjamina</i> Linn <sup>167</sup>	Moraceae	Leaves
<i>Bauhinia purpurea</i> Linn <sup>168</sup>	Cesalpiniaceae	Leaves
<i>Solanum nigrum</i> <sup>169</sup>	Solanaceae	Whole plant
<i>Ficus religiosa</i> Linn <sup>170</sup>	Moraceae	Stem bark
<i>Melia azhadirecta</i> Linn <sup>171</sup>	Piperaceae	Leaves
<i>Withania frutescens</i> <sup>172</sup>	Solanaceae	Leaves
<i>Valeriana wallichii</i> <sup>173</sup>	Valerianaceae	Roots

**CONCLUSION:** Liver is a vital organ play a major role in metabolism and excretion of body. Liver injury or liver dysfunction is a major health problem that challenges not only health care professionals but also the pharmaceutical industry and drug regulatory agencies. Few of the popular liver diseases are listed above. Herbal medicines have been used in the treatment of liver diseases for a long time. Several herbal preparations are available in the market. Many herbs have been proven to be efficient as hepatoprotective agents, and maximum of them are listed above.

**ACKNOWLEDGEMENT:** The authors are grateful to Mr. Pankaj S. Niranjana for their guidance and support during review preparation and also grateful to Dr. Shashi Alok for supervising the work.

**CONFLICT OF INTEREST:** Nil

## REFERENCES:

1. Mitish A, Sherif RZ and Bloomston M: Liver anatomy; Surgical clinics of North America 2010; 90(4): 643-53.
2. Etymology online hepatic, Retrieved December 12, 2013.
3. Etymology online hepatic, Retrieved December 12, 2013.
4. Cortan RS, Kumar V, Fausto N, Stanley RL and Abul AK: Robbins and Cortan pathologic basis of diseases; St. Louis, Mo: Elsevier Saunders 2005; 7: 878.
5. Tortora Derrickson 2008; 945.
6. Renz JF and Kinkhabwala M: Surgical anatomy of the liver; In Busuttill R.W, Klintmalm. G.B, Transplantation of the Liver, Elsevier 2014; 23-39.
7. Anatomy of liver; Liver.co.uk; Retrieved 2015: 6-26.
8. Kmiec Z: Cooperation of liver cells in health and diseases; Adv Anat Embryo Cell Bio 2001; 161(III-XII): 1-151.
9. Pocock G: Human physiology (3<sup>rd</sup> edn), Oxford Uni. Press 2006: 404.
10. Singh I: The liver pancreas and spleen; Textbook of Anatomy with colour Atlas, Jaypee Brothers 2008: 592-06.
11. Thatavarthi R, Kumar PR and Sreedevi: Racemethionine hepatoprotective activity against rifampicin induced hepatotoxicity in albino rats. Der Pharmacia Lettre 2011; 3(2): 396-06.
12. Orhan DD, Orhan N and Ergun F: Hepatoprotective effect of *Vitis vinifera* L. Leaves on carbon tetrachloride induced

- acute liver damage in rats. Journal of Ethnopharmacology 2007; 112: 145-51.
13. Dorland's: Dorland's illustrated medical dictionary, Elsevier, 32<sup>nd</sup> edn, 2012: 285.
  14. Häussinger, Dieter, ed; Liver regeneration, Berlin: De Gruyter 2011: 1.
  15. Robbins and Cortan pathologic basis of disease, 7<sup>th</sup> edn., 1999: 101.
  16. Chu J and Saddler K.C: "New school in liver development: Lessons from Zebrafish"; Hepatology 2009; 50(5): 1656-63.
  17. Councilman WT: "Two", Disease and its causes; New York Henry Holt and company, London Williams and Norgate, The University Press, Cambridge, USA 1913.
  18. Anatomy and physiology of the liver- Canadian cancer society; Cancer.ca. Retrieved 2015.
  19. Maton A, Hopkins J, Mc-Laughlin CW, Johnson S, Warner MQ, LaHart D and Wright JD: Human biology and health, Eaglewood cliffs, New Jersey, USA 1993.
  20. Zakim D and Boyer TD: Hepatology: A Textbook of Liver diseases, 4<sup>th</sup> edn 2002.
  21. Cirrhosis overview; National digestive diseases information, Clearinghouse, Retrieved 2010.
  22. Extraintestinal complications; Liver diseases; Crohn's and colitis foundation of America, Retrieved, 2010.
  23. Kumar CS, Balamurgan B, Murugeswan S, Natarajan P, Sharavan SP, Petchimuthu S and Murgan STS; Hepatoprotective activity of leaves and roots extracts of *Moringa oleifera* Lam; International Journal of Microbiology Research 2010; 1(12): 90-93.
  24. Richardo: Carbontetrachloride hepatotoxicity. Pharmacological Review 1967; 19: 145-208.
  25. Mitchell JR, Jollow DJ, Potter WZ, Gillette JR and Brodie BB: Acetaminophen-induced hepatic necrosis. IV. Protective role of glutathione. Journal of Pharmacology and Experimental Therapeutics 1973; 187: 211-17.
  26. Huggette HPI, Hylands PJ, Mensah AY, Hensel A and Deters AM: *In-vitro* tests and ethnopharmacological investigations: wound healing as an example. Journal of Ethnopharmacology 2005; 100(1-2): 100-07.
  27. Prescott LF: Hepatotoxicity of mild analgesic; British Journal of Clinical Pharmacology 1980; 10(S 2): 373S-379S.
  28. Coles B, Wilson I, Wardman P, Hinson JA, Nelson SD and Ketterer B: The spontaneous and enzymatic reaction of N-acetyl-p-benzoquinimine with glutathione: a stopped-flow kinetic study. Archives Biochemistry and Biophysics 1988; 264: 253-60.
  29. Nakamura W, Hosoda S and Hayachi K: Purification and properties of rat liver glutathione peroxidase. Biochem Biophy Acta 1997; 358: 251-61.
  30. Wojcicki J, Samocholec L and Hinek A: The effect of cernitin TM on galactosamine-induced hepatic injury in rats; Graminex: "Your botanical source" 1984; 2: 1-5.
  31. Koff RS, Gordon G and Sabesin SM: D-galactosamine hepatitis: 1. Hepatocellular injury and fatty liver following a single dose. Proceeding of the Society of Experimental Biology and Medicine 1971: 137-696.
  32. Pickering RW, James GWL and Parker FL: An investigation of some parameters that affect the galactosamine model of hepatitis in the rats. Arzneimittel forsh, 1975; 23: 1591-92.
  33. Hunter AL, Holsher MA and Neal RA: Thioacetamide-induced hepatic necrosis, I, Involvement of the mixed function oxidase-enzyme system. Journal of Pharmacology and Therapeutics 1977; 200: 439-48.
  34. Porter WR, Gudzinowcz MJ and Neal RA: Thioacetamide induced hepatic necrosis, II, the pharmacokinetics of thioacetamide and thioacetamide S-oxide in the rats. Journal of Pharmacology and Experimental Therapeutics 1979; 208: 386-91.
  35. Ahmad F and Tabassum N: Experimental models used for the study of antihepatotoxicity agents. Journal of Acute Diseases 2012; 85-89.
  36. Smuckler EA: Alcoholic drink: Its production and effects. Fed Proe 1975; 34: 2038-44.
  37. Orhan DD, Orhan N and Ergun F: Hepatoprotective effect of *Vitis vinifera* L. leaves on carbon tetrachloride induced acute liver damage in rats. Journal of Ethnopharmacology 2007; 112: 145-51.
  38. Ward FM and Daly MJ: Hepatic diseases; Clinical pharmacy and therapeutics. Churchill Livingstone, New York 1999; 195-212.
  39. Saleem TSM, Chetty CM, Ramkanth S, Rajan VST, Kumar KM and Gauthaman K: Hepatoprotective herbs- a review. International Journal of Research in Pharmaceutical Sciences 2010; 1(1): 1-5.
  40. Rajib A, Monirul JKM, Musaddik A and HaqueE: Hepatoprotective activity of methanol extract of some medicinal plants against carbon tetrachloride-induced hepatotoxicity in albino rats. Global Journal of Pharmacology 2009; 3(3): 116-22.
  41. Yar HS, Ismail DK and Alhamed MN: Hepatoprotective effect of *Carthamus tinctorius* L. against carbontetrachloride-induced hepatotoxicity in rats. Pharmacie Globale International Journal of Comprehensive Pharmacy 2012; 9(12): 1-5.
  42. Pradeep KS: Hepatoprotective activity of *Ardisia solanacea* in carbon tetrachloride-induced hepatotoxic albino rats. Asian Journal of Research in Pharmaceutical Sciences 2013; 3(2): 79-82.
  43. Jameel A, Sunil N, Vipul D, Anuja P, Sagar K, Pal S, Subash M and Shashikant P: Hepatoprotective activity of methanol extract of aerial parts of *Delonix regia*; Pharmacology 2011; 1(5): 118-22.
  44. Mukul KG and Dasgupta S: Role of plant metabolites in toxic liver injury. Asian Pacific Journal of Clinical Nutrition 2002; 1(11): 48-50.
  45. Pushpalatha M and Ananthi T: Protective effect of *Solanum pubescens* Linn. on CCl<sub>4</sub> induced hepatotoxicity in albino rats. Mintage journal of Pharmaceutical and Medicinal Sciences 2012; 1(1): 11-13.
  46. Mohammed HH: Protective effect of *Coriandrum sativum* plant of hepatotoxicity and nephrotoxicity induced by carbon tetrachloride in male albino rats. The 6<sup>th</sup> Arab and 3<sup>rd</sup> International annual scientific conference on: Development of higher specific education programs in Egypt and the Arab World in the light of knowledge era requirements, April 2011: 13-14.
  47. Rajesh K, Sushil K, Arjun P and Jayalakshmi S: Hepatoprotective activity of aerial parts of *Plumbago zeylanica* Linn. against carbon tetrachloride-induced hepatotoxicity in rats. International Journal of Pharmacy and Pharmaceutical Sciences 2009; 1(11): 171-75.
  48. Arjumand A, Reddy KS and Reddy CS: Hepatoprotective activity of *Cardiospermum helicacabum* stems extracts against carbon tetrachloride-induced hepatotoxicity in wistar rats. International Journal of Pharmaceutical Sciences and Nanotechnology 2009; 2(1): 488-92.
  49. Ulanganathan I, Divya D, Radha K, Vijyakumar TM and Dhanaraju MP: Protective effect of *Luffa acutangula* (Var) amara against carbon tetrachloride-induced hepatotoxicity

- in experimental rats. Research Journal of Biological Sciences 2010; 5(9): 615-24.
50. Hewawasam RP, Jayatilaka KAPW, Pathirana C and Mudduwa LKB: Hepatoprotective effect of *Epaltes divaricata* extract on carbon tetrachloride induced hepatotoxicity in mice. Indian Journal of Medical Research 2004; 30-34.
  51. Ranjan KG, Bose A and Mishra SK: Hepatoprotective activity of *Tagetes erecta* against carbon tetrachloride induced hepatic damage in rats. Acta poloniae pharmaceutical – Drug Research 2011; 68(6): 999-03.
  52. Parameshwar P, Reddy YN and Devi MA: Hepatoprotective and antioxidant activities of *Ziziphus rotundifolia* (Linn.) against carbon tetrachloride induced hepatic damage in rats. International Journal of Pharmaceutical Sciences and Nanotechnology 2012; 5(3): 1775-79.
  53. Ugwueze ME, Adonu CC and Attama AA: Evaluation of the hepatoprotective activity of root extracts of *Millettia abonesis* on carbon tetrachloride-induced hepatotoxicity in rats; Int. J of Adv Res 2013; 1(15): 65-70.
  54. Mohan GK, Pallavi E, Kumar BR, Ramesh M and Venkatesh S: Hepatoprotective activity of *Ficus carica* Linn. leaf extract against carbon tetrachloride-induced hepatotoxicity in rats; DARU 2007; 15(3): 162-66.
  55. Hogade MG, Patil KS, Wadkar GH, Mathapati SS and Dhumal PB: Hepatoprotective activity of *Morus alba* (Linn.) leaves extract against carbon tetrachloride-induced hepatotoxicity in rats. African Journal of Pharmacy and Pharmacology 2010; 4(10): 731-34.
  56. Patience OO, Festus BC, Philip FU, Nneka RN, Ijeoma EA and Nkemakonam CO: Phytochemical analysis, hepatoprotective and antioxidant activity of *Alchornea cordifolia* methanol leaf extract on carbon tetrachloride-induced hepatic damage in rats. Asian Pacific Journal of Tropical Medicine 2012; 289-93.
  57. Isaias BR, Maria del Rayo CC, Pilar CR, Hector GLG, Dalila CN, Francisco JAM and Elsa MTC: Hepatoprotective effect of *Leucophyllum frutescens* on Wistar albino rats intoxicated with carbon tetrachloride; Annals of Hepatology 2007; 6(4): 251-54.
  58. Karunakar HE and Arun BJ: Hepatoprotective effect of *Carissa carandas* Linn. root extract against carbon tetrachloride and paracetamol-induced hepatic oxidative stress. Indian J of Experimental Biology 2009; 47(8): 660-67.
  59. Nwachukwu DC, Okwuosa CN, Chukwu PU, Nkiru AN and Udeani T: Hepatoprotective activity of methanol extract of the seeds of *Sesamum indicum* in carbon tetrachloride-induced hepatotoxicity in rats; India. J of Novel Drug Delivery 2011; 3(1): 36-42.
  60. Gnanaprakash K, Chetty CM, Ramkanth S, Alagusundaram M, Tiruvengadarajan. VS, Parmeswarina SA and Saleem TSM: Aqueous extract of *Flacourtia indica* prevents carbon tetrachloride-induced hepatotoxicity in rats. Int J of Bio and Life Sci 2010; 6(1): 51-55.
  61. Gayathiri S, Ventriselvan S, Shankar J, Ishwin S, Devi H, Kaur S and Yaashini A: Hepatoprotective activity of aqueous extract of *Hippophae rhamnoides* L. in carbon tetrachloride-induced hepatotoxicity in albino wistar rats; Int J of Bio and Pharmaceu Res 2012; 3(4): 531-37.
  62. Bahar A, Tanveer A, Manoj V and Shah AK: Hepatoprotective activity of two plants belonging to the Apiaceae and the Euphorbiaceae family. Journal of Ethnopharmacology 2002; 79: 313-16.
  63. Ning W, Peibo L, Yonggang W, Wei P, Zhong W, Suiyi T, Shaoling L, Xiao S and Weiwei S: Hepatoprotective effect of *Hypericum japonicum* extract and its fractions. J. of Ethnoph 2008; 116(1): 1-6.
  64. Akram E, Pejman M, Maryam B and Jalal Z: Hepatoprotective activity of Cinnamon ethanolic extract against CCl<sub>4</sub> induced liver injury in rats. EXCLI Journal 2012; 11: 495-07.
  65. Takate SB, Pokharkar RD, Chopade VV and Gite VN: Hepatoprotective activity of the aqueous extract of *Launaea intybaceae* (Jacq) Beauv against carbon tetrachloride induced hepatic injury in albino rats. J of Pharma Sci and Tech 2010; 2(7): 247-51.
  66. Rekha R, Hemamalini S, Akasakalai K, Krishna CHM, Bavan S, Vittal and Sundaram RM: Hepatoprotective activity of *Mimosa puduca* leaves against carbon tetrachloride induced toxicity. J of Nat Pro 2009; 2: 116-22.
  67. Sakthidevi G, Alagammal M and Mohan VR: Evaluation of hepatoprotective and antioxidant activity of *Polygala javana* DC whole plant – CCl<sub>4</sub> induced hepatotoxicity in rats. Int J of Pharmaceu and Chem Sci 2013; 2(2): 764-70.
  68. Divya B, Praneetha P, Rani VS and Kumar BR: Hepatoprotective effect of whole plant extract fractions of *Marsilea minuta* linn. Asian Journal of Pharmaceutical and Clinical Research 2013; 6(3): 100-07.
  69. Manisha S, Shete RV, Kore KJ and Attal AR: Hepatoprotective activity of *Ficus bengalensis* Linn. Leaves. Current Pharma Research 2012; 2(12): 503-07.
  70. Durga PN, Dinda SC, Swain PK, Kar B and Patro VJ: Hepatoprotective activity against CCl<sub>4</sub> induced hepatotoxicity in rats of *Chenopodium album* aerial parts. J of Phytotherapy and Pharmacology 2012; 1(2): 33-41.
  71. Chanchal KR and Das AK: Effect of *Psidium guajava* Linn. methanolic leaf extract on hepatoprotection. J of Pharmaceu and Biomed Sci 2010; 1(3).
  72. Prakash T, Snehal DF, Raj SU, Surendra V, Goli D, Perfect S and Kotresha D: Hepatoprotective activity of leaves of *Rhododendron arboreum* in CCl<sub>4</sub> induced hepatotoxicity in rats. J of Medicinal Plants Research 2008; 2(11): 315-20.
  73. Shrinivas. B and Suresh RN: Hepatoprotective activity of methanolic extract of *Dipteracanthus patulus* (JACQ) NEES: possible involvement of antioxidant and membrane stabilization property. Int J of Pharm and Pharma Sci 2012; 4(2): 685-690.
  74. Amrita R, Ajay KS, Neelima S and Sanjeev KS: Hepatoprotective and antioxidants activity of ethanolic extract of *Cuscutta reflexa* roxb. IOSR J of Pharm 2012; 2(2): 142-47.
  75. Yok A, Tomoyuki K, Chika M, Manami M, Chiho I, Shizula K and Toshio I: Free radical scavenging and hepatoprotective actions of the medicinal herb, *Crassocephalum crepidiodes* from the Okinawa Islands. Biological and Pharma Bulletin, 28(1), 2005; 19-25.
  76. Rajesh MG and Latha MS: Protective activity of *Glycyrrhiza glabra* Linn. on carbon tetrachloride-induced peroxidative damage. Ind J of Pharmaco 2004; 36: 284-87.
  77. Akram J, Fatema F, Zohreh S and Hossein N: Hepatoprotective activity of *Gundelia tourenfortii*. J of Ethnopharm 2005; 101(1-3): 233-37.
  78. Xingshen Y, Xibin F, Yao T, Kwan-Ming NG, Yanbo Z, Jun T, Jiangang S and Seiichi K: Hepatoprotective effects of *Captidis rhizome* aqueous extract on carbon tetrachloride-induced hepatotoxicity in rats. J of Ethnopharmacology 2009; 124(1): 130-36.

79. Adeneye AA, Olagunju JA, Banju AAF, Abdul SF, Sanusi OA, Sanni OO, Osarodion BA and Shoniki OE: The aqueous seed extract of *Carica papaya* Linn. Prevents carbon tetrachloride-induced hepatotoxicity in rats. *Int J of Appl Res in Nat Pro* 2009; 2(2):19-32.
80. Akram J, Mohammad JK, Zahra D and Hossein N: Hepatoprotective activity of *Circhorium intybus* Linn. Leaves extract against carbon tetrachloride-induced hepatotoxicity. *Iranian J of Pharma Res* 2006; 1: 41-46.
81. Praveen TK, Dharmaraj S, Jitendra B, Dhanabal SP, Manimaran S, Nanjan MJ and Rema R: Hepatoprotective activity of petroleum ether, diethyl ether, methanol extract of *Scoporia dulcis* Linn. against carbon tetrachloride induced acute liver injury in mice. *Indian J of Pharmacology* 2009; 41(3): 110-14.
82. Meenakshisundaram S, Devaki T and Rayeem M: Protective effects of *Indigofera tinctorial* Linn. against D-galactosamine and carbon tetrachloride challenge on in-situ perfused rat liver. *Ind J of Physiology and Pharmacology* 2001; 45(4): 428-34.
83. Shahjahan M, Sabitha KE, Mallika J and Shayamala Devi CS: Effect of *Solanum trilobatum* against carbon tetrachloride-induced hepatic damage in albino rats; *Ind. J of Medical Research* 2004; 120: 194-98.
84. Mankani KL, Krishna V, Manjunatha BK, Vidya SM, Singh SDJ, Manohar YN, Rahman AUR and Avinash KR: Evaluation of the hepatoprotective activity of stem bark of *Pterocarpus marsupium* Roxb. *Ind J of Pharmacology* 2005; 37: 165-68.
85. Manjunatha KL: Hepatoprotective activity of *Pterocarpus santalinus* LF, endangered medicinal plant. *J of Pharmacology* 2006; 38(1): 25-28.
86. Venukumar MR and Latha MS: *Curculigo orchioides* in carbon tetrachloride-induced hepatotoxicity in rats. *Ind J of Clinical Biochemistry* 2002; 17(2): 80-87.
87. Qarashi AL, Ali HMM and Samy WAR: Protective effects of extracts from Dates (*Phoenix dactylifera* L.) on carbon tetrachloride-induced hepatotoxicity in rats. *Int J of App Res in Veteri Med* 2004; 2(3): 176-80.
88. Hewawasam RP, Jayatilaka KAPW, Parthirana C and Mudduwa LKB: Protective effect of *Asteracantha longifolia* extract in mouse liver injury induced by carbon tetrachloride and paracetamol. *J of Pharmacy and Pharmacology* 2003; 55(10): 1413-18.
89. Sanmugapriya E and Venkataraman S: Studies on hepatoprotective and antioxidant actions of *Strychnos potatutum* Linn. seeds on carbon tetrachloride induced acute hepatic injury in experimental rats. *J of Ethno Pharmacology* 2006; 105(1-2): 154-60.
90. Manjunatha BK and Vidya SM: Hepatoprotective activity of *Vitex trifolia* against carbon tetrachloride induced hepatic damage. *Ind J of Pharmace Sci* 2008; 70(2): 241-45.
91. Aghel N, Rashidi I and Mombein A: Hepatoprotective activity of *Capparis spinosa* root bark against carbon tetrachloride induced hepatic damage in mice. *Iranian J of Pharmaceutical Research* 2007; 6(4): 285-90.
92. Ahmed S, Rahman A, Alam A, Saleem M, Athar M and Sultan S: Evaluation of the efficacy of *Lawsonia alba* in the alleviation of carbon tetrachloride-induced oxidative stress. *J of Ethnopharmacol* 2000; 69(2): 157-64.
93. Sumaria S, Muhammad RK and Rahmat AK: Hepatoprotective effects of methanol extract of *Carissa opaca* leaves on carbon tetrachloride-induced against in rats. *BMC Complementary and Alternative medicines* 2011; 11: 48.
94. Arthika S, Shanthammal Y, Igal NS, Elankini P, Ganesan R, Gaidhani SN and Reddy GP: Hepatoprotective activity of the ethanolic extract of *Azima tetraacantha* against paracetamol-induced hepatotoxicity in wistar albino rats. *J of Adv in Pharma and Healthcar Res* 2011; 1(2): 14-21.
95. Pallab KH, Moulisha B, Sanjib B, Tarum KK and Ashoke KG: Hepatoprotective activity of *Dregea volubilis* fruit against paracetamol-induced liver damage in rats. *Ind J of Pharmaceu Edu and Res* 2012; 46(1): 17-22.
96. Arun KS and Eswar KK: Hepatoprotective activity of aqueous fruit extract of *Coccinia indica* against paracetamol-induced hepatotoxicity in rats. *Int J of Res in Pharmaceu and Biomed Sci* 2013; 4(1): 179-82.
97. Ramadoss S, Kannan K, Balamurugan K, Jeganathan NS and Manavalan R: Evaluation of hepatoprotective activity in the ethanolic extract of *Sida rhombifolia* Linn. against paracetamol-induced hepatic injury in albino rats. *Res J of Pharmaceu Bio and Chem Sci* 2012; 3(1): 497-02.
98. Hemamalini K, Krishna VR, Bhargav DRA and Vasireddy DRU: Hepatoprotective activity of *Tabebuia rosea* and *Solanum pubescens* against paracetamol-induced hepatotoxicity in rats. *Asi J of Pharmaceu and Clin Res* 2012; 5(4): 153-56.
99. Deepak KD, Veerendra CY, Siva S, Tirtha G, Rajalingam D, Pinaki S, Bhim CM and Tapan KM: Evaluation of the hepatoprotective and antioxidant activity of *Ichnocarpus frutescens* (Linn.) R.Br. on paracetamol induced hepatotoxicity in rats. *Tro J of Pharmaceu Res* 2007; 6(3): 755-65.
100. Geegi PG, Anitha P, Sany AA and Kanimozhi R: Hepatoprotective activity of *Vanilla planifolia* against paracetamol-induced hepatotoxicity in albino rats. *Int J of Inst Pharma and Lifesci* 2011; 1(3): 70-74.
101. Rani KU, Amirtham D and Nataraja TS: Hepatoprotective activity of *Nilgiranthus ciliatus* (Nees) Bremek in paracetamol-induced hepatotoxicity in wistar albino rats. *Afri J of Int Medi* 2013; 1(4): 26-30.
102. Simon RP, Hitesh VP and Kiran K: Hepatoprotective activity of some plant extracts against paracetamol-induced hepatotoxicity in rats. *J of Herbal Medicine and Toxicology* 2010; 4(2): 101-06.
103. Manokaran S, Jaswanth A, Sengotturelu S, Nandhakumar J, Duraisamy R, Karthikeyan D and Mallogaswari R: Hepatoprotective activity of *Aerva lanata* Linn. against paracetamol-induced hepatotoxicity in rats. *Res J of Pharmacy and Technology* 2008; 1(4): 398-00.
104. Asif L, Bolay B, Das M, Debmalaya M, Sudipta K, Samit B and Amalesh S: Hepatoprotective activity of ethanolic extract of *Aerva sanguinolenta* (Amaranthaceae) against paracetamol induced liver toxicity in wistar rats. *NSHM Journal of Pharmacy and Healthcare Management* 2012; 03: 57-65.
105. Asma R, Hemamalini K, Shashi PG and Uma V: Hepatoprotective activity of *Gymnosporia emerginata* (Wild.) and *Marsdenia volubilis* (Linn. F) stapf against paracetamol-induced hepatotoxicity in rats. *Int J of Curr Pharmaceu Rev and Res* 2013; 4(2): 36-41.
106. Karunakar ME and Arun BJ: Hepatoprotective effect of *Carissa carandas* Linn. root extract against carbon tetrachloride and paracetamol-induced hepatic oxidative stress. *Ind J of Exp Bio* 2009; 47(8): 650-67.
107. Rahiman OMF, Kumar MR, Mani TT, Niyas KM, Kumar BS, Phaneendra P and Surendra B: Hepatoprotective activity of *Asparagus racemosus* root on liver damage caused by paracetamol in rats. *Ind J of Novel Drug Delivery* 2011; 3(2): 112-17.

108. Hemamalini K, Preethi B, Bhrgava A and Uma V: Hepatoprotective activity of *Kigelia africana* and *Anogeissus accuminata* against paracetamol-induced hepatotoxicity in rats. *Int J of Pharmaceu and Biomed Res* 2012; 3(3): 152-56.
109. Abhishek KS, Sanjiv S and Chandel HS: Evaluation of the hepatoprotective activity of *Abelmoschus moschatus* seeds in paracetamol induced hepatotoxicity in rats. *IOSR J of Pharma* 2012; 2(5): 43-50.
110. Samaresh D, Sushmita D, Nayak SS and Subas CD: Hepatoprotective activity of *Cyperus articulatus* Linn. against paracetamol-induced hepatotoxicity in rats. *J of Chem and Pharmaceu Res* 2013; 5(1): 314-19.
111. El-Banna H, Soliman M and Al-Wabel N: Hepatoprotective effects of thymus and saliva essential oils on paracetamol-induced toxicity in rats. *J of Physio and pharmaco adv* 2013; 3(2): 41-47.
112. Sabir SM, Ahmad SD, Hamid A, Khan MQ, Athayde ML, Santos DB, Boligon AA and Rocha JBT: Antioxidant and hepatoprotective activity of Ethanolic extract of leaves of *Solidago microglossa* containing polyphenolic compounds. *Food Chemistry* 2012; 131(3): 741-47.
113. Parmar HB, Das SK and Gohil KJ: Hepatoprotective activity of *Macrotyloma uniflorum* seed extract on paracetamol and D- galactosamine induced liver toxicity in albino rats. *Int J of Pharmacological Res* 2012; 2(2): 86-91.
114. Shardul SW and Gangadhar BS: Antioxidant and hepatoprotective activity of *Tridax procumbens* Linn. against paracetamol-induced hepatotoxicity in male albino rats. *Adv Studies in Bio* 2010; 2(3): 105-12.
115. Maheshwari C, Maryammal R and Venkatanarayanan R: Hepatoprotective activity of *Orthosiphon stamineus* on liver damage caused by paracetamol in rats. *Jordan J of Bio Sci* 2008; 1(3): 105-08.
116. Jayadeviah KV, Bhat KI, Joshi AB, Vijaykumar MMJ and Pinkey R: Hepatoprotective activity of *Desmodium oojeinense* (ROXB) H. Ohashi against paracetamol-induced hepatotoxicity. *Asian J of Pharmaceu and Healthcare Sciences* 2012; 2(2): 312-15.
117. Mehta RS, Shankar MB, Geetha M and Saluja AK: Preliminary evaluation of the hepatoprotective activity of *Trianthema protulacastrum* Linn. *J of Natural Remedies* 2003; 3(2): 180-84.
118. Sheshidhar GB, Yasmeen AM, Arati C, Sangappa VK, Pundarikaksha HP, Dombale V and Manjula R: Evaluation of hepatoprotective activity of ethanolic extract of *Accacia catechu* wild in paracetamol-induced hepatotoxicity in albino rats. *Int J of Pharmaceu and Bio Sci* 2013; 3(2): 264-70.
119. Arshed ID, Saxena RC and Bansal SK: Assessment of hepatoprotective activity of fruit pulp of *Feronia limonia* (Linn) against paracetamol-induced hepatotoxicity in albino rats. *J of Natural Products Plant Resources* 2012; 2(2): 226-33.
120. Singh D and Gupta RS: Hepatoprotective activity of methanolic extract of *Tecomella undulate* against alcohol and paracetamol-induced hepatotoxicity in rats. *Life Sciences and Medicine Research* 2011; 26.
121. Raju RW, Radhika SS, Kunal MT, Kalpana SP and Sunil SJ: Screening of roots of *Baliospermum montanum* for hepatoprotective activity against paracetamol-induced liver damage in albino rats. *Int J of Green Pharmacy* 2008; 2: 220-28.
122. Kiran PM, Raju AV and Rao BG: Investigation of hepatoprotective activity of *Cyathea gigantea* (Wal. and Ex. Hook) leaves against paracetamol-induced hepatotoxicity in rats. *Asian Pacific J of Tropical Biomedicine* 2012; 2(5): 352-56.
123. Kumar SVS, Sujatha C, Syamala J, Nagasudha B and Mishra SH: Hepatoprotective effect of root extract of *Operculina turpethum* Linn. leaves against paracetamol-induced hepatotoxicity in rats. *Ind J of Pharmaceu Sci* 2006; 68: 32-35.
124. Pimple BP, Kadam PV, Badgujar NS, Bafna AR and Patil MJ: Protective effect of *Tamarindus indica* Linn. against paracetamol-induced hepatotoxicity in rats. *Ind J of Pharmaceu Sci* 2007; 69: 827-31.
125. Kanda SYM, Veerendra CM, Bhim MC and Kumar T: Hepatoprotective and antioxidant role of *Berberis tinctoria* Lesch. Leaves on paracetamol induced hepatic damage in rats. *Iranian J of Pharmaco and Therapeutics* 2006; 4(1).
126. Chattopadadhayay RR and Bandyopadhayay M: Possible mechanism of hepatoprotective effect of *Azadirachta indica* leaf extract against paracetamol-induced hepatic damage in rats, part III. *Ind J of Pharmaco* 2005; 37: 184-85.
127. Nirmal KB, Neeraj K and Mishra SH: Protective effect of stem bark of *Ceiba pentandra* Linn. against paracetamol-induced hepatotoxicity in rats. *Pharmacognosy Research* 2010; 2(1): 28-30.
128. Kanchana N and Sadiq AM: Hepatoprotective effect of *Plumbago zeylanica* on paracetamol induced liver toxicity in rats. *Int J of Pharma and Pharmaceu Sci* 2011; 3(1): 151-54.
129. Malar HLV and Bai SMM: Hepatoprotective activity of *Phyllanthus emblica* against paracetamol-induced hepatic damage in wistar albino rats. *African Journal of Basic and Applied Sciences* 2009; 1(1-2): 21-25.
130. Shyamal S, Latha PG, Shine VJ and Devi TG: Hepatoprotective effects of *Pittosporum neelgherrense* on D- galactosamine (d-galn) induced liver injury in rats. 04-24.
131. Swarnalatha L and Reddy PN: Hepatoprotective activity of *Sphaeranthus amaranthoides* on D- galactosamine-induced hepatitis in albino rats; *Asian Pacific Journal of Tropical Biomedicine* 2012; S1900-S1905.
132. Pandian S, Badami S and Shankar M: Hepatoprotective activity of methanolic extract of *Oldenlandia herbacea* against D- galactosamine-induced hepatotoxicity in rats. *Int J of App Res in Nat Pro* 2008; 6(1): 16-19.
133. Pradeep D, Tanaji N, Singh RM, Anil M and Nithin J: Hepatoprotective activity of *Calotropis gigantea* root bark experimental liver damage induced by D-Galactosamine in rats. *Int J of Pharmaceutical Science and Nanotechnology* 2008; 1(3): 281-86.
134. Ganesan R, Venkatanarasimhan M, Sharad P, Reddy GP, Anandan T and Masilamani G: Hepatoprotective effect of *Coldenia procumbens* Linn. against D- galactosamine-induced acute liver damage in rats. *Int J of Integrative Sciences, Innovation and Technology* 2013; 2(2): 9-11.
135. Prabhakaran V, Kumar BSA, Shekhar DS, Nandeesh R, Subramanyam P and Ranganayakulu D: Evaluation of the hepatoprotective activity of *Portulaca oleracea* L. on D- Galactosamine induced hepatic injury in rats. *Boletin Latinoamericano y del Caribe be Plantas Medicinales y Aromáticas* 2010; 9(3): 199-05.
136. Duraiswamy B, Kumar MNS, Gupta S, Rawat M, Porwa O and Murugan R: Hepatoprotective activity of *Betula utilis* bark on D-galactosamine-induced hepatic insult. *World J of Pharmacy and Pharmaceutical Sci* 2012; 1(1): 456-71.
137. Dhanabal P, Syamala EK and Suresh B: Protective and therapeutic effects of the Indian medicinal plant *Pterocarpus santalinus* on D-galactosamine induced liver

- damage. Asian J of Traditional Medicines 2007; 2(2): 51-57.
138. Dhanabal SP, Jain R, Priyanka DL, Murugananthan N and Raghu PS: Hepatoprotective activity of *Santolina chamaecyparissus* Linn. against D-galactosamine induced hepatotoxicity in rats. Pharmacognosy communication, 2012; 2(2): 67-70.
  139. Dhanabai SP, Syamala G, Kumar MNS and Suresh B: Hepatoprotective activity of the Indian medicinal plant *Polygala arvensis* on D- galactosamine-induced hepatic injury in rats. Fitoterapia 2006; 77(6): 472-74.
  140. Jaishree V and Shailappa BS: Antioxidant and Hepatoprotective effect of Swertiamarin from *Enicostemma axillare* against D-galactosamine induced acute liver damage in rats. J of Ethnopharmacology 2010; 130(1): 103-06.
  141. Kyo-Ho H, Naoto H, Ken-ichiro S, Mitsu OS, Takahiro N, Hiroaki Y, Makoto H, Hideyuki C, David LT and Michihiro F: Hepatoprotective effect of purple potato extract against D-galactosamine induced liver injury in rats. Bioscience 2006; 70(6): 1432-37.
  142. Oluwatosin AA and Edward OA: Hepatoprotection on D-galactosamine induced toxicity in mice by purified fractions from *Garcinia kola* seeds. Basic and Clinical Pharmacology and Toxicology 2006; 98(2): 135-41.
  143. Anshu R, Kumar SA, Annie S and Singh RAK: Hepatoprotective potential of *Fumaria indica* pugsleys whole plant extract, fractions and an isolated alkaloid protopine. Phytomedicines 2008; 15(6-7): 470-77.
  144. Kotoky J, Dasgupta B and Sarma GK: Protective properties of *Leucas havendulaefolia* extracts against D-galactosamine induced hepatotoxicity in rats. Fitoterapia 2008; 79(4): 290-92.
  145. Ambarasu C, Raj Kapoor B, Bhatt KS, John G, Amuthan AA and Satish K: Protective effect of *Pisonia aculeate* on thioacetamide-induced hepatotoxicity in rats. Asian Pacific Journal of Tropical Biomedicine 2012; 2(7): 511-15.
  146. Zahra AA, Mohamed AA, Mustafa K, Ali HM and Mahmood A: Gene expression profiling reveals underlying molecular mechanism of hepatoprotective effect of *Phyllanthus niruri* on thioacetamide-induced hepatotoxicity in Spargue Dawley rats. BMC Complementary and Alternative Medicine 2013; 13:60 doi: 10.1186/1472-6882-13-160.
  147. Farkaad AK, Normadiyah MK, Mahmood A and Wageeh AY: Hepatoprotective role of ethanolic extract of *Vitex negundo* in thioacetamide induced liver fibrosis in male rats; Evidence-based elementary and alternative medicine 2013. doi: 10.1111.1155/2013/739850.
  148. Kumar P, Rao GD, Lakshmayya and Setty SR: Hepatoprotective effect of ethanol extract of tubers of *Momordica tuberosa* cogn. In thioacetamide-induced hepatic damage. Pharmacologyonline 2008; 3: 181-89.
  149. Fakad AK, Faizah O, Mahmood AA, Farida H and Pouya H: Effect of *Tinospora crispa* on thioacetamide induced liver cirrhosis in rats. Ind J of Pharmacology 2011; 43(1): 64-68.
  150. Kumar SP, Asdaq SMB, Kumar NP, Asad M and Khajuria DK: Protective effect of *Zizyphus jujuba* fruit extract against paracetamol and thioacetamide induced hepatic damage in rats. The Internet J of Pharmacology 2009; 7(1): Doi: 10.558/2991.
  151. Mohamad BA, Hasona NAS and Selemin HAH: Protective effects of extract from Dates (*Phoenix dactylifera* L.) and ascorbic acid-induced hepatotoxicity in rats. Iranian J of Pharmaceutical Research 2008; 7(3): 193-01.
  152. Prabha SP, Ansil PN, Nitha A, Willa PJ and Latha MS: Preventive and curative methanolic extract of *Gardenia gummifera* Linn. on thioacetamide-induced oxidative stress in rats. Asian Pacific J of Tropical Disease 2012; 90-98.
  153. Shirode DS, Jain BB, Kumar CBM and Setty SR: Hepatoprotective and antioxidant effects of *Albizia lebbbeck* against thioacetamide-induced hepatotoxicity in rats. J of Chemical and Pharmaceutical Sciences 2012; 5: 199-04.
  154. Pallab KH, Gupta M, Upal KM, Chandi CK and Laxmanan M: Hepatoprotective effect of *Wedelia calendulaceae* against thioacetamide induced liver damage in rats. Pharmacology Online 2007; 3: 414-21.
  155. Bhushan G, Kavimani S and Raj Kapoor B: Protective effect of *C. pentandra* on thioacetamide-induced hepatotoxicity in rats. Int J of Biological and Pharmaceutical Research 2012; 3(1): 23-29.
  156. Said AS, Mahmood A, Salim AA, Suzy MS, Sidding IA and Hamid AH: *Ipomoea aquatica* extract shows protective action against thioacetamide-induced hepatotoxicity. Molecules 2012; 17: 6145-55. doi: 10.3390/molecules17056146.
  157. Venkatesh P, Dinakar A and Senthikumar N: Screening of hepatoprotective and antioxidant activity of alcoholic and aqueous extracts of *Boerhaavia diffusa* and *Anisochilus carnosus*. Int J of Pharmacy and Pharmaceutical Sciences 2013; 5(2): 208-211.
  158. Nilesh KJ and Abhay KS: Protective effects of *Phyllanthus acidus* (L.) stem leaves extract on acetaminophen and thioacetamide-induced hepatic injuries in Wistar rats. Asian Pacific Journal of Tropical Medicines 2011; 470-474.
  159. Azam R, Shahnaz SF, Saeed CA, Hydar A, Ali Z, Maryam A and Hasan Y: The effect of *Artemisia aucheri* extract on hepatotoxicity induced by thioacetamide in male rats. Avicenna J of Phytomedicine 2013; 3940: 293-01.
  160. Shamshun N and Kumari M: Ameliorating effect of *Nigella sativa* oil in thioacetamide induced liver cirrhosis in albino rats. Indian J. of Pharmaceutical Education and Research 2013; 47(2): 135-39.
  161. Suzy MS, Mahmood AA, Ahmed SA, Ismail S, Salim SA and Shahram G: Hepatoprotective effect of ethanolic extract of *Curcuma longa* on thioacetamide liver cirrhosis in rats. BMC Complementary and Alternative Medicine 2013; 13: 56.
  162. Mahesh KJ, Sunil K and Srivastava B: Hepatoprotective activity of *Capparis deciduas* on liver damage caused by thioacetamide in male wistar rats. Int J of Toxicology and Pharmacology Res 2010; 2(3): 92-94.
  163. Suzy M, Ahmed SALM and Mahmood A: Efficacy of *Bosenbergia rotunda* treatment against thioacetamide-induced liver cirrhosis in the rat model. Evidence-Based Complementary and Alternative Medicine 2012.
  164. Sharma P, Bhodhankar SL and Thakurdesai PA: Protective effect of *Feronia elephantum correa* leaves on thioacetamide-induced liver necrosis in diabetic rats. Asian Pacific Journal of Tropical Biomedicine 2012; 2(9): 691-95.
  165. Eduardo MS, Eduardo MB, Isela AG, María TSM, José GS, Mirandeli B, Ángel MG, Manuel García-Lunay GR, Leopoldo AFJ and José AMG: Review of natural products with hepatoprotective effects. World Journal of Gastroenterology 2014; 20(4): 14787-804.
  166. Kumar A: A review on hepatoprotective herbal drugs. Int J of Res in Pharmacy and Chemistry 2012; 2(1): 92-02.



167. Kanaujia VK, Irechaiya R, Singh HK, Kailasiya D, Verma M, Yadav RD and Shivhare D: Evaluation of the hepatoprotective activity of *Ficus benjamina* leaves. J Nat Pro Plant Reso 2011; 193: 59-69.
168. Rani IV, Veena G, Raju MB, Tejeswani G, Bhaskar GU and Sowmya P: Evaluation of Hepatoprotective activity of *Bauhinia purpurea* Linn. Int J of Res in Pharmaceu and Biomed Sci 2011; 2(3): 1389-93.
169. Elhag RAM, Badwi SMAE, Bakhiet AO and Galal M: Hepatoprotective activity of *Solanum nigrum* extracts on chemically induced liver damage in rats. Journal of Veterinary Medicine and Animal Health 2011; 3(4): 45-50.
170. Suryavanshi K, Khakre S, Chourasia A, Chaurasiya PK, Pawar RS and Deenanath J: Hepatoprotective activity of stem bark extract of *Ficus religiosa* induced hepatic damage. Ind J of Pharmaceu Sci 2008; 70: 241-45.
171. Rajeswari H, Vasuki R, Samudram P and Geetha A: Hepatoprotective action of ethanolic extracts of *Melia azedarach* Linn. and *Piper longum* Linn. and their combination on CCl<sub>4</sub> induced hepatotoxicity in rats. Ind J of Exp Bio 2011; 49: 276-81.
172. Montilla MP, Cabo J, Navarro MC, Risco S, Jimenez J and Aneiros J: The protective and curative action of *Withania frutescens* leaf extract against CCl<sub>4</sub> induced hepatotoxicity. Phytotherapy Research 1990; 4: 212-15.
173. Syed SK, Rizvi W, Kumar A and Khan A: A study to evaluate the antioxidant and hepatoprotective activity of aqueous extracts of roots of *Valeriana wallichii* in CCl<sub>4</sub> induced hepatotoxicity in rats. Int J Basic Clin Pharmaco 2014; 1(2): 354-58.

**How to cite this article:**

Chanchal DK, Rashi S, Niranjana PS, Alok S and Rajput R: Medicinal Plants used in hepatoprotective: a review. Int J Life Sci & Rev 2016; 2(4): 61-77. doi: 10.13040/IJPSR.0975-8232.IJLSR.2(42).61-77.

All © 2015 are reserved by International Journal of Life Sciences and Review. This Journal licensed under a Creative Commons Attribution-NonCommercial-ShareAlike 3.0 Unported License.

This article can be downloaded to **ANDROID OS** based mobile. Scan QR Code using Code/Bar Scanner from your mobile. (Scanners are available on Google Playstore)